

## ORIGINAL ARTICLE

# Is Spastic Muscle Echo Intensity Related to the Response to Botulinum Toxin Type A in Patients With Stroke? A Cohort Study

Alessandro Picelli, MD, Paola Bonetti, MD, Carla Fontana, MD, Martina Barausse, MD, Francesca Dambruoso, MD, Francesca Gajofatto, MD, Paolo Girardi, MSc, Mario Manca, MD, Raffaele Gimigliano, MD, Nicola Smania, MD

**ABSTRACT.** Picelli A, Bonetti P, Fontana C, Barausse M, Dambruoso F, Gajofatto F, Girardi P, Manca M, Gimigliano R, Smania N. Is spastic muscle echo intensity related to the response to botulinum toxin type A in patients with stroke? A cohort study. *Arch Phys Med Rehabil* 2012;93:1253-8.

**Objective:** To investigate the relationship between gastrocnemius muscle echo intensity and response to botulinum toxin type A (BoNT-A) in patients with spastic equinus foot resulting from stroke.

**Design:** Cohort study.

**Setting:** University hospital.

**Participants:** Adult patients (N=56) with spastic equinus foot resulting from stroke scheduled to receive BoNT-A injection into the gastrocnemius muscle.

**Interventions:** All patients were injected with BoNT-A (abobotulinumtoxinA) into the gastrocnemius muscle with an ultrasonography-guided, multisite injection technique. The toxin dose was 250U for the gastrocnemius medialis and 250U for the gastrocnemius lateralis (dilution 500U/2mL) in each patient. All patients were evaluated before and 4 weeks after BoNT-A injection.

**Main Outcome Measures:** Spastic gastrocnemius muscle echo intensity visually graded with the Heckmatt scale. Clinical assessment of the spastic gastrocnemius with the Modified Ashworth Scale, Tardieu Scale, and ankle passive range of motion.

**Results:** Postintervention testing at 4 weeks showed overall significant improvements in the clinical assessment of the spastic gastrocnemius muscle. No significant change was observed in the echo muscle intensity of the spastic gastrocnemius after BoNT-A injection. Post hoc comparisons showed that all clinical outcomes were significantly better in those patients with echo muscle intensity of the spastic gastrocnemius graded II on the Heckmatt scale than those with grades III ( $P < .001$ ) and IV ( $P < .001$ ) after botulinum toxin injection.

**Conclusions:** These findings support the hypothesis that patients with higher spastic muscle echo intensity have a reduced response to BoNT-A.

**Key Words:** Fibrosis; Muscle, skeletal; Muscle spasticity; Rehabilitation; Ultrasonography.

© 2012 by the American Congress of Rehabilitation Medicine

**STROKE IS ONE OF THE MAIN** causes of morbidity in Western countries.<sup>1</sup> Damage to the sensory-motor networks and descending tracts results in the positive and negative signs of upper motor neuron syndrome.<sup>2</sup> Spasticity is one of the main features of upper motor neuron syndrome, which is defined as a state of increased muscle tone with exaggerated reflexes.<sup>3</sup> It is clinically characterized by a velocity-dependent increase in the resistance to passive movement, and may interfere with motor function, leading to the need for clinical interventions such as drugs, physiotherapy, or other rehabilitation procedures.<sup>2-5</sup>

Botulinum toxin type A (BoNT-A) has been proven to be effective and safe in the treatment of focal spasticity.<sup>5</sup> It acts in the cytosol of nerve endings and inhibits the release of acetylcholine at neuromuscular junctions by cleaving the synaptosomal-associated protein of 25kDa, which is required for vesicle docking and, consequently, neurotransmitter release.<sup>5,6</sup> The major causes for the loss of BoNT-A response in adult patients with focal spasticity are the following: inaccurate selection and identification of the correct muscle for injection, insufficient drug dosages, inadequate injection technique, development of changes in the muscle, and formation of neutralizing antibodies.<sup>7</sup>

The ultrasonography-guided technique allows one to perform visually controlled and anatomically precise injections of BoNT-A into spastic muscles.<sup>8,9</sup> The use of ultrasound guidance has been reported to improve the effectiveness of BoNT-A selective neuromuscular blocking of the gastrocnemius muscle in patients with spastic equinus foot, consistent with the accuracy of muscle identification and needle placement in the muscle mass.<sup>10-12</sup> Clinical experience with the use of ultrasound guidance for BoNT-A injection showed that ultrasonography could also be a useful tool for evaluating the morphology of spastic muscles. Indeed, spasticity leads to the development of changes in the muscle structure over time by increasing intramuscular connective tissue and fat content.<sup>13</sup> The disruption of normal muscle architecture caused by the

From the Neuromotor and Cognitive Rehabilitation Research Center, Department of Neurological, Neuropsychological, Morphological and Movement Sciences (Picelli, Bonetti, Fontana, Barausse, Dambruoso, Gajofatto, Smania), and the Unit of Epidemiology and Medical Statistics, Department of Public Health and Community Medicine (Girardi), University of Verona, Verona; University of Rome "La Sapienza," Rome (Picelli); Motion Analysis Laboratory, San Giorgio Hospital, Ferrara (Manca); Second University of Naples, Naples (Gimigliano); and Neurological Rehabilitation Unit, Azienda Ospedaliera-Universitaria Integrata, Verona (Smania), Italy.

No commercial party having a direct financial interest in the results of the research supporting this article has or will confer a benefit on the authors or on any organization with which the authors are associated.

Correspondence to Nicola Smania, MD, Neuromotor and Cognitive Rehabilitation Research Center, Dept of Neurological, Neuropsychological, Morphological and Movement Sciences, University of Verona, Italy, P.le L.A. Scuro, 10. 37134 Verona, Italy, e-mail: [nicola.smania@univr.it](mailto:nicola.smania@univr.it). Reprints are not available from the author.

In-press corrected proof published online on Apr 12, 2012, at [www.archives-pmr.org](http://www.archives-pmr.org).

0003-9993/12/9307-0103\$36.00/0

doi:10.1016/j.apmr.2012.02.005

## List of Abbreviations

BoNT-A	botulinum toxin type A
MAS	Modified Ashworth Scale
PROM	passive range of motion
TS	Tardieu Scale

infiltration of fat and the development of fibrosis has been reported to increase reflections of the ultrasound beam, resulting in an increased echo intensity of spastic muscles.<sup>13</sup> Based on this, and taking into account that the development of changes in the muscle structure has been reported to influence the BoNT-A effect,<sup>7</sup> it is conceivable that spastic muscles with higher echo intensity may have a reduced response to BoNT-A. However, to date, no study has evaluated the association between echo intensity and response to BoNT-A in spastic muscles.

The main aim of this study was to investigate the relationship between gastrocnemius muscle echo intensity and the response to BoNT-A in adult patients with spastic equinus foot resulting from stroke. The secondary aim was to examine the relationship between spastic muscle echo intensity and severity of spasticity in patients with stroke.

## METHODS

Inclusion criteria were as follows: age greater than 18 years, occurrence of spastic equinus foot as a consequence of ischemic or hemorrhagic stroke (documented by computed tomography scan or magnetic resonance imaging, subarachnoid hemorrhage excluded), gastrocnemius muscle spasticity graded at least 1+ on the Modified Ashworth Scale (MAS),<sup>14</sup> time from stroke onset of at least 6 months, and no BoNT-A injection into the affected leg muscles or any rehabilitative treatment in the last 3 months before recruitment. Exclusion criteria were as follows: fixed contractures or bony deformities of the affected leg, previous treatment of the affected leg spasticity with neurolytic or surgical procedures, and other neurologic or orthopedic conditions involving the affected leg. All participants were outpatients and gave their informed consent for participation in the study. The study was carried out according to the Declaration of Helsinki and was approved by the local ethics committee.

### Treatment Procedures

BoNT-A (abobotulinumtoxinA) 500U diluted with 2mL of saline 0.9% was injected into the gastrocnemius muscle of the affected leg.<sup>15</sup> Even if the recommended dilution of abobotulinumtoxinA for spasticity is 500U/1mL, in our clinical experience, a dilution of 500U/2mL is well tolerated and easier to manage in the treatment of gastrocnemius muscle. The injection sites were determined using anatomic landmarks and the ultrasonography-guided technique. Injections were performed at 2 sites in each head of the gastrocnemius muscle: near the muscle origin (proximal site) and at the midbelly of the muscle bulk (distal site).<sup>10</sup> The BoNT-A dose was 250U for the gastrocnemius medialis and 250U for the gastrocnemius lateralis (125U per injection site) in each patient.<sup>7,15</sup>

Patients did not undergo any form of therapy aimed at increasing the effectiveness of BoNT-A (such as electrical stimulation, casting, taping, stretching, or physical therapy) during the study.

### Evaluation Procedures

The following outcome measures were evaluated in all patients immediately before (t<sub>0</sub>) and 4 weeks after (t<sub>1</sub>) BoNT-A injection: spastic gastrocnemius muscle echo intensity, gastrocnemius muscle spasticity, and ankle passive range of motion (PROM) of the affected leg.

The same examiner (A.P.) performed B-mode, real-time ultrasonography with a linear transducer (scanning frequency, 10MHz)<sup>a</sup> to evaluate the gastrocnemius muscle of the affected leg. All patients remained in the prone position with their leg

outstretched during the whole procedure. The transducer was positioned at the midbelly of the muscle bulk, perpendicular to the gastrocnemius surface, and placed gently on the skin using water-soluble transmission gel to avoid any pressure-induced alterations of the muscle tissue.<sup>10</sup> The muscle echo intensity of the spastic gastrocnemius was visually evaluated in the transverse view using the Heckmatt scale: grade I, normal; grade II, an increase of muscle echo intensity while bone echo is still distinct; grade III, a marked increase in muscle echo intensity and a reduced bone echo; grade IV, a very high muscle echo intensity and complete loss of bone echo (fig 1).<sup>13,16</sup>

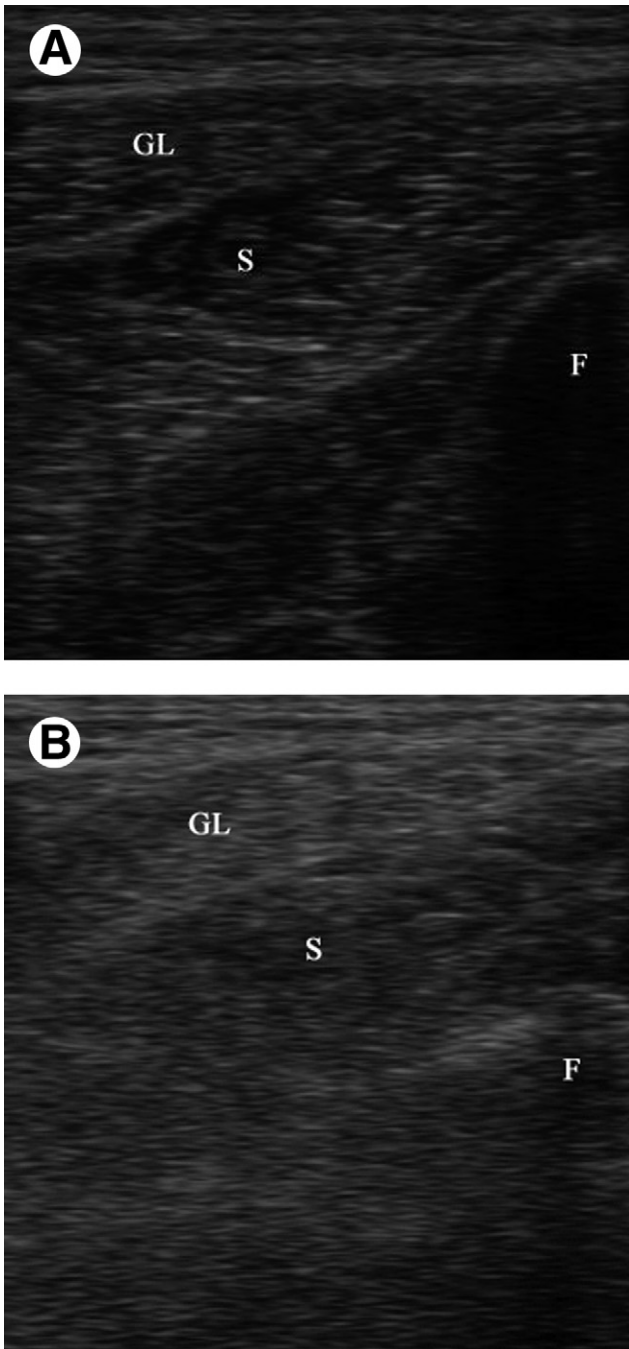
Gastrocnemius muscle spasticity was evaluated at the affected leg by means of the MAS<sup>14</sup> and the Tardieu Scale (TS).<sup>17</sup> The MAS is a 6-point scale grading the resistance of a relaxed limb to rapid passive stretch (0, no increase in muscle tone; 1, slight increase in muscle tone at the end of the range of motion; 1+, slight increase in muscle tone through less than half of the range of motion; 2, more marked increase in muscle tone through most of the range of motion; 3, considerable increase in muscle tone; 4, joint is rigid).<sup>14</sup> For statistical purposes, a score of 1 was considered a 1, while a score of 1+ was considered a 2 and so on, until 5.<sup>18</sup> The TS evaluates spasticity using 2 measures: the spasticity grade (a 5-point scale grading the quality of muscle reaction to stretch) and the spasticity angle (the angle at which muscle reaction occurs).<sup>17,19</sup> It can be performed at 3 velocities: as slow as possible (V1), falling under gravity (V2), and as fast as possible (V3).<sup>17</sup> To mainly evaluate stretch-induced muscle activity, we graded spasticity by rating the quality of muscle reaction at V3.<sup>17,20</sup> We also decided not to provide data about the spasticity angle because, in our view, they might be confounded with other ankle articular angle measures reported in this study. The TS spasticity grading is as follows: 0, no resistance through the course of the passive movement; 1, slight resistance throughout the course of the passive movement arc with no clear catch at a precise angle; 2, clear catch occurring at a precise angle, interrupting the passive movement followed by a release; 3, fatigable clonus (<10s) occurring at a precise angle; 4, infatigable clonus (>10s) occurring at a precise angle.<sup>17</sup> Ankle PROM was measured at the affected leg using a hand-held goniometer. We arbitrarily decided the sensitivity of the measurement in 5° and designated the dorsiflexion angle as positive and the plantar flexion angle as negative, considering the neutral position of the joint as 0°. The MAS, TS, and ankle PROM were evaluated by the same examiner with each patient in the supine position and the knee fully extended. The examiner (P.B.) was blinded to the spastic gastrocnemius muscle echo intensity of patients.

### Statistical Analysis

The Wilcoxon signed-ranks test on the pretreatment/post-treatment scores was carried out for all the outcome measures. The Kruskal-Wallis test was used to verify the difference in distribution among the MAS, TS, ankle PROM, confounding variables (sex, age, time from onset), and Heckmatt scale. To assess the association between clinical outcomes t<sub>1</sub>–t<sub>0</sub> difference and the Heckmatt scale, the Spearman rank correlation test was performed. Multiple comparisons in the Heckmatt scale were evaluated with post hoc Tukey tests for the MAS, TS, and ankle PROM. The alpha level for significance was set at *P*<.05. Statistical analysis was carried out using R 2.9.2 for Windows.<sup>b</sup>

## RESULTS

Fifty-six persons (36 men, 20 women; mean age ± SD, 59.2±14.1y) with spastic equinus foot resulting from stroke



**Fig 1.** Ultrasonographic imaging (transverse view) of the spastic gastrocnemius muscle in a patient with Heckmatt grade II (A) and Heckmatt grade IV (B). Abbreviations: F, fibula; GL, gastrocnemius lateralis; S, soleus.

(mean time from onset  $\pm$  SD,  $5.3 \pm 2.3$ y) were recruited from among 123 outpatients consecutively admitted to our neurologic rehabilitation unit during the period from January 2010 to March 2011. There were no dropouts. All patients had previously received BoNT-A injections into the triceps surae (gastrocnemius muscle and/or soleus): 19 patients had received less than 3 treatments with BoNT-A, while 37 patients had received BoNT-A 3 or more times before being enrolled in the study. Patients' characteristics are detailed in table 1.

As reported in table 2, at 4 weeks after BoNT-A injection, significant improvements were observed in the MAS, TS, and ankle PROM, while no change was found in the Heckmatt grade. Multiple independent-sample Kruskal-Wallis tests showed a significant different distribution between the MAS ( $P=.003$ ;  $K=11.506$ ), TS ( $P=.027$ ;  $K=7.222$ ), and ankle PROM ( $P=.017$ ;  $K=8.148$ ) measured at t0 and the muscle echo intensity graded on the Heckmatt scale. As reported in table 3, a significant difference in distribution was also observed between the Heckmatt grade and improvements in the MAS, TS, and ankle PROM at t1.

The Spearman correlation showed a significant association between the t1–t0 difference of the MAS ( $P<.001$ ;  $\rho=.704$ ), TS ( $P<.001$ ;  $\rho=.438$ ), ankle PROM ( $P<.001$ ;  $\rho=-.732$ ), and Heckmatt grade. With a consideration of these results about the MAS, the power calculation size estimated that a sample size of 56 patients provides 99% power to detect a significant correlation.

As reported in table 4, post hoc Tukey tests showed significant differences between patients with echo muscle intensity of the spastic gastrocnemius graded II or III on the Heckmatt scale in the MAS ( $P<.001$ ), TS ( $P<.001$ ), and ankle PROM ( $P<.001$ ) at the t1 versus t0 evaluation. Moreover, significant differences were observed between patients with echo muscle intensity of the spastic gastrocnemius graded II or IV on the Heckmatt scale in the MAS ( $P<.001$ ), TS ( $P<.001$ ), and ankle PROM ( $P<.001$ ). No significant difference was observed between patients with echo muscle intensity of the spastic gastrocnemius graded III or IV on the Heckmatt scale (see table 4).

## DISCUSSION

Our results support the hypothesis that patients with higher spastic muscle echo intensity have a reduced response to BoNT-A. Indeed, we observed that patients with echo intensity of the spastic gastrocnemius graded II on the Heckmatt scale (corresponding to an increase of muscle echo intensity while bone echo is still distinct) showed better improvements in spasticity (as measured with the MAS and TS) than those with higher muscle echo intensity after the injection of the same dose of BoNT-A. Furthermore, as measured by the ankle PROM, patients showed a significant reduction of response to BoNT-A according to the increase of spastic gastrocnemius muscle echo intensity.

After stroke, the decreased voluntary motor unit recruitment leaves joints immobilized, with the paretic muscles (ie, upper limb internal rotators, pronators, and flexors; lower limb extensors) placed in a shortened position.<sup>21</sup> Immobilization leads to the development of muscle contracture with a loss of muscle mass and sarcomeres, accumulation of intramuscular connective tissue, increased intramuscular fat content, and degenerative changes at the myotendinous junction with a decreased tensile strength.<sup>21</sup> Muscle overactivity, which is defined as an increased involuntary motor unit recruitment, gradually arises

**Table 1: Demographic and Clinical Features of Patients**

Parameter	Heckmatt II (n=16)	Heckmatt III (n=22)	Heckmatt IV (n=18)
Age (y)	51.5 $\pm$ 18.6	60.9 $\pm$ 12.4	63.9 $\pm$ 8.3
Sex (men/women)	11/5	14/8	11/7
Disease duration (y)	4.4 $\pm$ 2.4	5.2 $\pm$ 1.7	6.2 $\pm$ 2.7
MAS	2.6 $\pm$ 0.5	2.7 $\pm$ 0.5	3.2 $\pm$ 0.5
TS	2.8 $\pm$ 0.8	2.2 $\pm$ 0.4	2.4 $\pm$ 0.6
Ankle PROM (deg)	-10.6 $\pm$ 8.1	-9.5 $\pm$ 8.0	-16.1 $\pm$ 5.3

NOTE. Values are mean  $\pm$  SD or n.



Table 2: Pretreatment/Posttreatment Comparisons in All Outcome Measures

Outcome Measure	Pretreatment	Posttreatment	Pretreatment/Posttreatment Comparison <i>P</i> (Z)
Hekmatt grade (I–IV)	3.0 (2.0 to 4.0)	3.0 (2.0 to 4.0)	NS
MAS (0–5)	3.0 (2.8 to 3.0)	2.0 (2.0 to 3.0)	<.001 (–4.817)
TS (0–5)	2.0 (2.0 to 3.0)	2.0 (2.0 to 2.0)	<.001 (–4.119)
Ankle PROM (deg)	–10.0 (–20.0 to –5.0)	–5.0 (–15.0 to 0.0)	<.001 (–5.179)

NOTE. Values are median (interquartile range) or as otherwise indicated. Abbreviation: NS, not significant.

in patients with disrupted central execution of voluntary commands, leading to the chronic aggravation of muscle contracture, which, in turn, enhances responses to stretch and further aggravates spastic overactivity.<sup>21,22</sup> Botulinum toxin produces a chemodeneration of muscles by impairing the release of acetylcholine from presynaptic nerve terminals at the neuromuscular junction.<sup>5,6</sup> In patients with focal spasticity, BoNT-A can be considered a first-line treatment to reduce muscle overactivity.<sup>7,23</sup> The progressive substitution of the contractile component of muscle with noncontractile tissue (ie, connective tissue and fat) leads to the loss of BoNT-A response in adult patients with focal spasticity.<sup>7,21,22</sup>

Ultrasonography allows the quantification of the disruption of normal muscle architecture in spastic muscles by evaluating their echo intensity.<sup>13</sup> Our findings showed that patients with a higher echo intensity of the spastic gastrocnemius muscle have a reduced response to BoNT-A. On this basis, one may argue that BoNT-A treatment would not be useful in these patients, suggesting that injections should be done earlier (before changes in the muscle structure develop). Moreover, it could be hypothesized that to obtain a significant reduction of spasticity, the toxin dosage needs to be increased. Otherwise, stretching or casting might be added in those spastic muscles with higher degrees of echo intensity.

It is worth noting that BoNT-A produces some effects on the muscular tissue as observed not only in a rodent model (the development of atrophy and related myofibrillar structural changes has been reported after toxin injection),<sup>24</sup> but also in healthy volunteers and patients with stroke.<sup>25,26</sup> As to humans, long-term magnetic resonance imaging alterations (atrophy and fatty infiltration) have been detected 1 year after a single dose of BoNT-A into the gastrocnemius lateralis of healthy volunteers,<sup>25</sup> and ultrasonography modifications (atrophy and reduced pennation angle) have been found 2 months after BoNT-A injection into the gastrocnemius medialis of patients with stroke.<sup>26</sup> In this study, no modification of the Hekmatt grading was observed at t1. Further studies with a longer follow-up (>1 mo) are needed to evaluate modification of spastic muscle echo intensity after BoNT-A injection.

In patients with spasticity, the increased resistance to passive movement is related not only to stretch reflex hyperactivity but

also to nonreflex biomechanical changes of muscles.<sup>27,28</sup> In a recent study, Gao et al<sup>29</sup> evaluated changes in passive mechanical properties of the gastrocnemius muscle in patients with stroke by means of a custom knee-ankle evaluation device and ultrasonography. The authors observed that decreased fascicle length, reduced pennation angle, and increased stiffness of the medial gastrocnemius were correlated with reduced ankle PROM and increased ankle joint stiffness in adult patients with spastic equinus foot resulting from stroke.<sup>29</sup> In the present study, we clinically evaluated patients by means of the MAS, TS, and ankle PROM. The MAS evaluates spasticity by grading the resistance to rapid passive movement but is unable to differentiate neural (ie, stretch reflex hyperactivity) from peripheral (ie, nonreflex biomechanical changes of muscles) factors in spastic muscles.<sup>20</sup> On the other hand, the TS performed at V3 (fast velocity stretch) has been reported to have a significant relationship with the laboratory measurement of stretch-induced muscle activity in patients with spastic ankle plantar flexors.<sup>17,20</sup> Ankle PROM has been described to correlate with changes in passive mechanical properties of the gastrocnemius muscle in patients with stroke.<sup>20</sup> Our results showed a significant association between the MAS, TS, ankle PROM, and gastrocnemius muscle echo intensity in adult patients with spastic equinus foot resulting from stroke. In our view, it is reasonable that the MAS and ankle PROM were related to changes (ie, fatty infiltration and fibrosis) in the spastic muscle structure (as measured by ultrasonography) because they allow the changes in the passive properties of muscles to be quantified. Conversely, our findings about the significant relationship observed between the TS performed at V3 (which mainly evaluates muscle overactivity) and spastic muscle echo intensity may appear quite unusual. Based on previous studies, this most likely occurred because the reduced extensibility of spastic muscles in a shortened position may produce a more ready transmission of any pulling force to muscle spindles, thus augmenting stretch reflexes.<sup>21</sup>

### Study Limitations

This study has several limitations. First, the small sample size may have hindered evaluation of a gradient correlation between spastic gastrocnemius echo intensity and response to BoNT-A.

Table 3: Distribution of the Main Characteristics of the Sample With Respect to the Hekmatt Grade and Associated Kruskal-Wallis Test

Parameter	Hekmatt Grade II	Hekmatt Grade III	Hekmatt Grade IV	<i>P</i> (K)
Sex (men)	68.8 (11)	63.6 (14)	61.1 (11)	.897 (.218)
Age (y)	55.0 (36.8 to 66.0)	64.0 (58.0 to 70.0)	63.5 (58.0 to 68.8)	.278 (2.562)
Time from onset (y)	4.0 (2.8 to 6.0)	5.00 (4.0 to 6.0)	6.0 (4.0 to 8.8)	.130 (4.085)
MAS t1–t0 difference	–1.0 (–1.3 to –1.0)	0.0 (–1.0 to 0.0)	0.0 (0.0 to 0.0)	<.001 (30.351)
TS t1–t0 difference	–1.0 (1.0 to –0.8)	0.0 (0.0 to 0.0)	0.0 (0.0 to 0.0)	<.001 (18.359)
Ankle PROM t1–t0 difference	10.0 (10.0 to 15.0)	5.0 (0.0 to 5.0)	0.0 (0.0 to 3.8)	<.001 (31.835)

NOTE. Values are % (n), median (interquartile range), or as otherwise indicated.

**Table 4: Post Hoc Comparisons in the Heckmatt Scale**

Parameter	Difference	95% CI	P
<b>MAS</b>			
Heckmatt III-II	0.88	0.54 to 1.23	<.001
Heckmatt IV-II	1.14	0.78 to 1.49	<.001
Heckmatt IV-III	0.25	-0.07 to 0.58	.17
<b>TS</b>			
Heckmatt III-II	0.80	0.41 to 1.19	<.001
Heckmatt IV-II	0.72	0.31 to 1.12	<.001
Heckmatt IV-III	-0.09	-0.46 to 0.29	.85
<b>Ankle PROM</b>			
Heckmatt III-II	-8.01	-10.85 to -5.17	<.001
Heckmatt IV-II	-10.49	-13.46 to -7.52	<.001
Heckmatt IV-III	-2.48	-5.22 to -0.27	.09

Abbreviation: CI, confidence interval.

Second, a computer-aided qualitative assessment of muscle echo intensity was not done. Pillen et al<sup>13</sup> reported that visual evaluation of muscle echo intensity (ie, Heckmatt scale) has a sensitivity of 71% versus an 87% sensitivity of computer-aided evaluation. Third, no independent person reassessed muscle echo intensity. Fourth, no electromyographic evaluation was made. The comparison of clinical, ultrasonographic, and electromyographic data could permit a more accurate interpretation of our findings. In particular, it would be interesting to investigate gait function in relation to the ultrasonographic aspect and activation pattern of spastic ankle muscles, taking into account, for example, the premature activity of the soleus muscle and its reduction after BoNT-A injection in patients with chronic stroke.<sup>30</sup> To further validate our findings, future studies involving a larger subject population and including a qualitative instrumental evaluation of spastic muscles echo intensity and muscle overactivity are needed. In addition, future studies aimed at understanding not only the role of BoNT-A treatment in spastic muscles with higher degrees of echo intensity but also the relationship between spastic muscle echo intensity and the functional status of patients are warranted.

### CONCLUSIONS

This study showed that patients with higher spastic muscle echo intensity have a reduced response to BoNT-A. This may suggest that BoNT-A treatment is not useful in these patients or, alternatively, that a higher dosage of BoNT-A is required to treat spastic muscles with higher degrees of echo intensity.

### References

- Sarti C, Rastenyte D, Cepaitis Z, Tuomilehto J. International trends in mortality from stroke, 1968 to 1994. *Stroke* 2000;31:1588-601.
- Lundström E, Smits A, Terént A, Borg J. Time-course and determinants of spasticity during the first six months following first-ever stroke. *J Rehabil Med* 2010;42:296-301.
- Lance JW. The control of muscle tone, reflexes and movement: Robert Wartenberg lecture. *Neurology* 1980;30:1303-13.
- Smania N, Picelli A, Munari D, et al. Rehabilitation procedures in the management of spasticity. *Eur J Phys Rehabil Med* 2010;46:423-38.
- Simpson DM, Gracies JM, Graham HK, et al. Assessment: botulinum neurotoxin for the treatment of spasticity (an evidence-based review): report of the Therapeutics and Technology Assessment Subcommittee of the American Academy of Neurology. *Neurology* 2008;70:1691-8.
- Aoki KR. Pharmacology and immunology of botulinum toxin type A. *Clin Dermatol* 2003;21:476-80.

- Wissel J, Ward AB, Erztgaard P, et al. European consensus table on the use of botulinum toxin type A in adult spasticity. *J Rehabil Med* 2009;41:13-25.
- Berweck S, Schroeder AS, Fietzek UM, Heinen F. Sonography-guided injection of botulinum toxin in children with cerebral palsy. *Lancet* 2004;363:249-50.
- Sconfienza LM, Lacelli F, Bruno A, Serafini G. Ultrasound guidance can improve the outcome of botulinum toxin A injection. *Eur J Phys Rehabil Med* 2009;45:153.
- Yang EJ, Rha DW, Yoo JK, Park ES. Accuracy of manual needle placement for gastrocnemius muscle in children with cerebral palsy checked against ultrasonography. *Arch Phys Med Rehabil* 2009;90:741-4.
- Py AG, Zein Addeen G, Perrier Y, Carlier RY, Picard A. Evaluation of the effectiveness of botulinum toxin injections in the lower limb muscles of children with cerebral palsy. Preliminary prospective study of the advantages of ultrasound guidance. *Ann Phys Rehabil Med* 2009;52:215-23.
- Kwon JY, Hwang JH, Kim JS. Botulinum toxin A injection into calf muscles for treatment of spastic equinus in cerebral palsy: a controlled trial comparing sonography and electric stimulation-guided injection techniques: a preliminary report. *Am J Phys Med Rehabil* 2010;89:279-86.
- Pillen S, van Keimpema M, Nivelstein RA, Verrips A, van Kruijsbergen-Raijmann W, Zwartz MJ. Skeletal muscle ultrasonography: visual versus quantitative evaluation. *Ultrasound Med Biol* 2006;32:1315-21.
- Bohannon RW, Smith MB. Interrater reliability of a Modified Ashworth Scale of muscle spasticity. *Phys Ther* 1987;67:206-7.
- Pathak MS, Nguyen HT, Graham HK, Moore AP. Management of spasticity in adults: practical application of botulinum toxin. *Eur J Neurol* 2006;13:42-50.
- Heckmatt JZ, Leeman S, Dubowitz V. Ultrasound imaging in the diagnosis of muscle disease. *J Pediatr* 1982;101:656-60.
- Gracies JM, Marosszeky JE, Renton R, Sandanam J, Gandevia SC, Burke D. Short-term effects of dynamic Lycra splints on upper limb in hemiplegic patients. *Arch Phys Med Rehabil* 2000;81:1547-55.
- Baricich A, Carda S, Bertoni M, Maderna L, Cisari C. A single-blinded, randomized pilot study of botulinum toxin type A combined with non-pharmacological treatment for spastic foot. *J Rehabil Med* 2008;40:870-2.
- Gracies JM, Lugassy M, Weisz DJ, Vecchio M, Flanagan S, Simpson DM. Botulinum toxin dilution and endplate targeting in spasticity: a double-blind controlled study. *Arch Phys Med Rehabil* 2009;90:9-16.
- Patrick E, Ada L. The Tardieu Scale differentiates contracture from spasticity whereas the Ashworth Scale is confounded by it. *Clin Rehabil* 2006;20:173-82.
- Gracies JM. Pathophysiology of spastic paresis. I: Paresis and soft tissue changes. *Muscle Nerve* 2005;31:535-51.
- Gracies JM. Pathophysiology of spastic paresis. II: Emergence of muscle overactivity. *Muscle Nerve* 2005;31:552-71.
- Simon O, Yelnik AP. Managing spasticity with drugs. *Eur J Phys Rehabil Med* 2010;46:401-10.
- Hassan SM, Jennekens FG, Veldman H. Botulinum toxin-induced myopathy in the rat. *Brain* 1995;118:533-45.
- Schroeder AS, Ertl-Wagner B, Britsch S, et al. Muscle biopsy substantiates long-term MRI alterations one year after a single dose of botulinum toxin injected into the lateral gastrocnemius muscle of healthy volunteers. *Mov Disord* 2009;24:1494-503.
- Tok F, Ozçakar L, Safaz I, Alaca R. Effects of botulinum toxin-A on the muscle architecture of stroke patients: an ultrasonographic study. *J Rehabil Med* 2011;43:1016-9.

27. de Vlugt E, de Groot JH, Schenkeveld KE, Arendzen JH, van der Helm FC, Meskers CG. The relation between neuromechanical parameters and Ashworth score in stroke patients. *J Neuroeng Rehabil* 2010;7:35.
28. Chung SG, van Rey EM, Bai Z, Roth EJ, Zhang L-Q. Biomechanic changes in passive properties of hemiplegic ankles with spastic hypertonia. *Arch Phys Med Rehabil* 2004;85:1638-46.
29. Gao F, Grant TH, Roth EJ, Zhang LQ. Changes in passive mechanical properties of the gastrocnemius muscle at the muscle fascicle and joint levels in stroke survivors. *Arch Phys Med Rehabil* 2009;90:819-26.
30. Hesse S, Krajnik J, Luecke D, Jahnke MT, Gregoric M, Mauritz KH. Ankle muscle activity before and after botulinum toxin therapy for lower limb extensor spasticity in chronic hemiparetic patients. *Stroke* 1996;27:455-6.

#### Suppliers

- a. GE Logiq Book XP; GE Medical Systems, 4855 West Electric Ave, Milwaukee, WI 53215.
- b. The R Project for Statistical Computing. Available at: <http://www.r-project.org>.